

## BSACI guidelines for the management of rhinosinusitis and nasal polyposis

G. K. Scadding\*, S. R. Durham†, R. Mirakian‡, N. S. Jones§, A. B. Drake-Lee¶, D. Ryan||, T. A. Dixon\*\*, P. A. J. Huber†† and S. M. Nasser‡

\*The Royal National Throat Nose & Ear Hospital, Gray's Inn Road, London, UK, †Department of Upper Respiratory Medicine, Imperial College, NHL1, London, UK,

‡Cambridge University NHS Foundation Trust, Allergy Clinic, Cambridge, UK, §Department of Otorhinolaryngology-Head & Neck Surgery, Queens Medical Centre,

Nottingham, UK, ¶University Hospital Birmingham, Edgbaston, Birmingham, ||Woodbrook Medical Centre, Loughborough UK, \*\*Royal Liverpool and Broadgreen

University Hospital NHS Trust, Liverpool, UK and ††British Society for Allergy and Clinical Immunology, London UK

### Clinical and Experimental Allergy

#### Summary

This guidance for the management of patients with rhinosinusitis and nasal polyposis has been prepared by the Standards of Care Committee (SOCC) of the British Society for Allergy and Clinical Immunology (BSACI). The recommendations are based on evidence and expert opinion and are evidence graded. These guidelines are for the benefit of both adult physicians and paediatricians treating allergic conditions. Rhinosinusitis implies inflammation of the nose and sinuses which may or may not have an infective component and includes nasal polyposis. Acute rhinosinusitis lasts up to 12 weeks and resolves completely. Chronic rhinosinusitis persists over 12 weeks and may involve acute exacerbations. Rhinosinusitis is common, affecting around 15% of the population and causes significant reduction in quality of life. The diagnosis is based largely on symptoms with confirmation by nasendoscopy. Computerized tomography scans and magnetic resonance imaging are abnormal in approximately one third of the population so are not recommended for routine diagnosis but should be reserved for those with acute complications, diagnostic uncertainty or failed medical therapy. Underlying conditions such as immune deficiency, Wegener's granulomatosis, Churg-Strauss syndrome, aspirin hypersensitivity and allergic fungal sinusitis may present as rhinosinusitis. There are few good quality trials in this area but the available evidence suggests that treatment is primarily medical, involving douching, corticosteroids, antibiotics, anti-leukotrienes, and anti-histamines. Endoscopic sinus surgery should be considered for complications, anatomical variations causing local obstruction, allergic fungal disease or patients who remain very symptomatic despite medical treatment. Further well conducted trials in clearly defined patient groups are needed to improve management.

**Keywords** allergen, anti-IgE, antihistamine, anti-leukotriene, aspirin, aspirin desensitization, BSACI, child, Churg-Strauss, computerized tomography (CT), corticosteroid, decongestant, fungal rhinosinusitis, guideline, IgE, immunotherapy, magnetic resonance (MRI), nasal polyps, nitric oxide, occupational, rhinosinusitis, sinusitis, skin prick test, surgery

#### Correspondence:

Dr S. M. Nasser, Cambridge University  
NHS Foundation Trust, Allergy Clinic,  
Cambridge, CB2 0QQ, UK.

E-mail: shuaib.nasser@  
addenbrookes.nhs.uk

#### Introduction

These guidelines for the management of patients with rhinosinusitis and nasal polyposis are intended for use by physicians practising in allergy. Evidence for the recommendations was obtained by employing electronic literature searches using the primary key words – sinusitis, rhinosinusitis, nasal polyps and fungal rhinosinusitis. Further searches were carried out by combining these search terms with asthma, antihistamine, anti-leukotriene, decongestant, child, surgery, magnetic resonance imaging

(MRI) computerized tomography (CT), aspirin and Churg-Strauss. Each article was reviewed for suitability for inclusion in the guideline. The recommendations were evidence graded at the time of preparation of these guidelines. The grades of recommendation and the levels of evidence are defined as in our previous guideline on urticaria [1]. During the development of these guidelines, a web-based system was employed to allow consultation with all British Society for Allergy and Clinical Immunology (BSACI) members. All comments and suggestions were carefully considered by the Standards of Care

Committee (SOCC). Where evidence was lacking a consensus was reached among the experts on the committee. Conflicts of interests were recorded by the SOCC, none jeopardized unbiased guideline development.

## Executive summary and recommendations

### Rhinosinusitis

- Rhinosinusitis implies inflammation of the nose and paranasal sinuses.
- The diagnosis of rhinosinusitis is primarily clinical and made on the history and examination with only a limited role for radiology (see text box 1).
- Sinus X-rays are rarely helpful and CT scans should be reserved for patients failing medical therapy or those with atypical or severe disease, i.e. unilateral symptoms, blood-stained discharge, displacement of the eye and severe pain.
- In epidemiological studies rhinosinusitis affects between 2% and 16% of the population.
- Acute rhinosinusitis lasts <12 weeks and usually follows a viral upper respiratory tract infection (UTRI).
- For acute rhinosinusitis the use of topical nasal corticosteroids or an antihistamine together with antibiotics is associated with more rapid resolution of symptoms (*grade of recommendation = A*).
- Chronic rhinosinusitis (CRS) lasts more than 12 weeks and usually responds incompletely to therapy, which may need to be continued long-term (*grade of recommendation = B*).
- Patients who fail initial medical therapy can respond to more specialized pharmacotherapy, which is as successful as surgery (*grade of recommendation = B*).
- Treating CRS, either medically or surgically, benefits accompanying asthma (*grade of recommendation = A*).
- Sinus surgery in children is of limited value and the disease in this age group often resolves spontaneously.
- Severe recurrent polypoid rhinosinusitis should prompt investigations for aspirin sensitivity, allergic fungal rhinosinusitis or Churg-Strauss syndrome.

### Nasal polyps

- Nasal polyps are not associated with allergy but can be associated with asthma, aspirin sensitivity, cystic fibrosis, allergic fungal sinusitis (AFS) and Churg-Strauss syndrome.
- At initial presentation all patients with polyps should be examined by an ear, nose, throat (ENT) surgeon.
- Unilateral polyps may be a sign of malignancy and should always be subject to ENT referral.
- Children with nasal polyps should be referred for further testing for cystic fibrosis.

- Aspirin sensitivity should be suspected in severely affected polyp patients, especially those with recurrent polyps and intrinsic asthma.
- The diagnosis of aspirin sensitivity relies upon either a clear history of two (or more) aspirin/non-steroidal anti-inflammatory drugs (NSAID)-induced reactions or by aspirin challenge, which can be nasal, inhaled, or oral.
- Aspirin challenge must be carried out only by doctors with appropriate experience and with full resuscitation facilities readily available.
- Patients with aspirin sensitivity should be warned to avoid all drugs with cyclooxygenase (COX) 1 inhibitory activity.
- Selective COX2 inhibitors appear to be safe in patients with aspirin sensitivity, although it is recommended that the first dose is administered in hospital under direct observation with monitoring for 2 h and resuscitation facilities readily available.
- Allergic fungal rhinosinusitis is rare in the United Kingdom, but more common in warmer climates such as the Southern USA and Australia.
- Allergic fungal rhinosinusitis is treated by surgery to remove infected tissue followed by topical corticosteroids.
- Chronic rhinosinusitis (CRS) accompanied by systemic symptoms and signs may indicate an underlying vasculitis or granulomatous disease.

### Rhinosinusitis

Sinusitis implies inflammation of the sinus linings but in practice rarely occurs without concomitant rhinitis; therefore, rhinosinusitis is the preferred term. Depending on the time course, rhinosinusitis is described as acute or chronic, with symptoms lasting under 12 weeks regarded as acute. In any individual, rhinosinusitis may be predominantly allergic, non-allergic, or infective, sometimes resulting from immune deficiency (innate or acquired). Mixed forms also occur. In epidemiological studies, rhinosinusitis affects between 2% and 16% of the population [2–4]

#### Text box 1: Rhinosinusitis – signs and symptoms

Major symptoms – *two of the following, one to be:*

- Nasal congestion or obstruction
- Nasal discharge (anterior or posterior) ±
  - Facial pain or pressure
  - Olfactory disturbance

AND either

*Endoscopic signs (one or more of):*

- Polyps
- Mucopurulent discharge from middle meatus
- Oedema/obstruction at middle meatus

OR

*Computerised Tomography (CT) signs, e.g.*

- Mucosal changes at ostiomeatal complex and/or in sinuses

## Classification

**Acute rhinosinusitis.** Acute rhinosinusitis is usually initially viral. Antibiotics are indicated for presumed bacterial superinfection and should only be prescribed if the symptoms are dramatic, i.e. maxillary pain, swelling and fever [5–7]. Analgesia and steam inhalation may offer symptomatic relief. The use of topical nasal corticosteroids [8, 9] or an antihistamine [10] together with antibiotics is associated with more rapid resolution of symptoms. In patients with symptoms persisting after 10 days, but without severe pain or fever, the use of douching and intra-nasal steroids alone could be considered [11]. Immediate referral is indicated for the symptoms as specified in text box 2.

### Text box 2: Symptoms warranting immediate referral

- Periorbital oedema
- Displaced globe
- Double vision
- Ophthalmoplegia
- Reduced visual acuity
- Severe unilateral or bilateral frontal headache
- Frontal swelling
- Signs of meningitis or focal neurologic signs

**Chronic rhinosinusitis.** CRS is a mucosal disease and structural abnormalities are not more common than they are in a control group [12]. The inflammation may be predominantly eosinophilic [allergic rhinitis (AR), non-AR with eosinophilia syndrome (NARES) and nasal polyps associated with aspirin sensitivity] or neutrophilic (immune deficiency, chronic infection and polyps in cystic fibrosis) [13].

## Diagnosis of rhinosinusitis

This is primarily a clinical diagnosis and made on history and examination.

## Signs and symptoms

### Rhinorrhoea

Rhinorrhoea is either anterior or leads to align post-nasal drip:

- Clear – infection unlikely
- Unilateral – is uncommon and cerebrospinal fluid (CSF) leak should be excluded [14]
- Coloured
  - yellow – allergy or infection
  - green – usually infection
  - blood tinged
    - unilateral – tumour, foreign body, nose picking, or misapplication of nasal spray

- bilateral – misapplication of nasal spray, granulomatous disorder, bleeding diathesis, or nose picking.

### Nasal obstruction

- Unilateral – usually septal deviation but also consider foreign body, antrochoanal polyp and tumours.
- Bilateral – may be septal (sigmoid) deviation but more likely rhinitis, or nasal polyps.
- Alternating – generalized rhinitis exposing the nasal cycle [15].

### Hyposmia or anosmia

- Mild transient – AR, viral infection.
- Intermittent – mucosal disease: nasal polyposis, infective rhinosinusitis, or rarely granulomatous disease.
- Complete – after head injury, and some neuropathic viruses, severe nasal polyposis, rarely anterior cranial fossa tumour, drug reactions, zinc deficiency, endocrine dysfunction, volatile gas exposure, ‘functional’, neuropsychiatric problems and idiopathic.
- Progressive may be associated with Parkinson’s disease, or either a personal or family history of Alzheimer’s dementia.

### Pain

- Alone – rarely due to rhinosinusitis – other causes of facial pain should be considered [16]
- With discharge and hyposmia – may accompany infective rhinosinusitis which:
  - May affect teeth, upper jaw, side of the face, behind the eye, or forehead
  - Usually responds to an appropriate antibiotic
  - In the absence of endoscopic or CT evidence of sinusitis, pain is unlikely to be attributable to sinus disease [16]
- Bilateral symmetrical symptoms of pressure without any other nasal symptoms or signs are due to mid-facial segment pain, a version of tension headache [17]
- Soreness of the hair bearing area inside the nasal vestibule may be due to an infective vestibulitis.

### Lower respiratory tract

Disorders of the upper and lower respiratory tract often co-exist:

- Most asthmatics have rhinitis – see rhinitis guidelines.
- In asthma with aspirin sensitivity – 36–96% have nasal polyps with rhinosinusitis [18] (see also ‘Aspirin-sensitive nasal polyposis’).
- Patients with ciliary dyskinesia may develop chronic infective rhinosinusitis, bronchiectasis and reduced fertility [19].

- Chronic obstructive pulmonary disease (COPD) patients may also have upper airway inflammation. COPD exacerbations are higher in those with frequent colds [20, 21].
- Nasal polyps can develop in up to 50% of patients with cystic fibrosis [22] (see also 'Nasal polyps (chronic polypoid rhinosinusitis)').

### Examination

#### Visual assessment

- Horizontal nasal crease across the dorsum of nose – supports a diagnosis of AR
- Depressed nasal bridge – post-surgery, Wegener's granulomatosis or cocaine misuse
- Widened bridge – polyps
- Purple tip in lupus pernio due to sarcoidosis
- An assessment of nasal airflow – (e.g. metal spatula misting)

#### Endoscopy

In order to diagnose rhinosinusitis, examination of the middle meatus with an endoscope is necessary. The examination includes:

- The appearance of the turbinates
- The presence/absence of purulent secretions
- The presence/absence of nasal polyps, but it may not be possible to see small ones
- Larger polyps can be seen at the nares and are distinguishable from inferior turbinate by their lack of sensitivity, yellowish grey colour and the ability to get between them and the side wall of the nose.
- Yellow sub-mucosal nodules with a cobblestone appearance suggest sarcoidosis [23].
- Crusting and granulations raise the possibility of vasculitis.
- Septal perforation may occur after septal surgery, due to chronic vasoconstriction (cocaine,  $\alpha$ -agonists), Wegener's granulomatosis, nose picking, very rarely steroid nasal sprays.

### Investigations

Allergen-specific IgE can be detected with skin prick tests (SPTs) or by serum immunoassay.

*Skin prick tests.* SPTs should be carried out routinely in all cases in order to determine if the rhinosinusitis is allergic or non-allergic. The results must be interpreted in the light of the clinical history.

*Serum total and specific immunoglobulin E.* Allergen-specific IgE usually correlates with the results of SPTs and nasal challenges, and may be requested when skin

tests are not possible or when the SPT together with the clinical history give equivocal results.

*Routine laboratory investigations.* Other investigations to help with the initial management of patients with rhinitis are guided by the findings from the history, examination and results of SPTs. Examples of laboratory investigations include:

- Full blood count (FBC) and differential white cell count.
- C-reactive protein (CRP).
- Anti-neutrophil cytoplasmic antibodies (ANCA) and, if positive, anti-proteinase-3 antibodies for Wegener's granulomatosis (positive in at least 60% of patients with limited Wegener's granulomatosis) and either myeloperoxidase or anti-proteinase-3 antibodies for Churg–Strauss (positive in approximately 50% of patients) [24].
- Angiotensin-converting enzyme may be raised in sarcoidosis [23].
- Thyroid function and thyroid auto-antibodies.
- Other auto-antibodies: anti-nuclear antibody (ANA), extractable-nuclear antigens (ENAs), if Sjogren's syndrome, or systemic lupus erythematosus (SLE) suspected.
- If AFS is suspected SPTs should be undertaken and specific IgE antibodies to aspergillus measured.
- Total Ig levels and specific antibodies and responses post-vaccination to tetanus, haemophilus and pneumococci if there is strong suspicion of antibody immunodeficiency from the history, e.g. chronic or recurrent purulent rhinosinusitis with recurrent infections elsewhere (particularly respiratory tract).
- Nasal smear/brushing for eosinophils.
- Microbiological examination of sputum and sinus swabs.
- Nasal secretions – CSF asialotransferrin for CSF rhinorrhoea.

*Olfactory tests.* The University of Pennsylvania Smell Identification Test (UPSIT) is well validated, can identify malingerers [25] and is accepted for legal cases.

*Cytology.* The techniques for obtaining cells for cytology in secretions, lavage, scraping, cotton pledgels, or brushings have not been standardized, nor have the criteria for evaluating cell counts [26]. Nevertheless the presence of eosinophils implies inflammation and may be helpful in predicting response to corticosteroids.

*Tests of mucociliary function.* Prolongation of saccharine clearance time suggests mucociliary dysfunction, either primary (rare) or secondary to infection, allergy or pollution [27]. However, a more accurate measure is the ciliary beat pattern and frequency observed from nasal brushings.

*Nasal nitric oxide.* Measurements of nitric oxide from the upper airway (FnNO, fractional nasal nitric oxide) are undergoing evaluation and are likely to be employed in the diagnosis of primary ciliary dyskinesia (where levels above 250 p.p.b. exclude the diagnosis) [28]. Normal levels may obviate the need for expensive, time-consuming tests of the ciliary beat frequency and electron microscopy of ciliary structure that are needed to establish the diagnosis. nNO measurements may also be useful in assessing the response to treatment in CRS and possibly for gauging ostiomeatal patency [29]. Low levels may also be found in severe nasal obstruction; high levels occur with inflammation.

*Exhaled nitric oxide.* Exhaled nitric oxide (eNO) (FeNO, fractional eNO) measurement can be useful clinically in the diagnosis and monitoring of asthma. Normal levels are <20 p.p.b., but become elevated in eosinophilic lower respiratory tract inflammation [30].

*Plain radiographs.* Plain radiographs have no place in the routine management of rhinosinusitis.

#### *Computerized tomography*

- Should be used and interpreted in the light of symptoms and endoscopic findings but is not a primary investigation in rhinosinusitis.
- In the diagnosis of rhinosinusitis, the use of CT alone can be misleading [31, 32] because approximately one-third of the population have abnormal CT scans.
- Has an invaluable role in defining the bony anatomy when surgery is planned, e.g. in the context of failed medical therapy for sinusitis [33].
- Is indicated in cases of diagnostic doubt, e.g. in the presence of unilateral nasal symptoms to exclude neoplasia.
- Has an important role in the management of the complications of rhinosinusitis [34] or in those in whom there are features suggestive of atypical or severe disease, i.e. unilateral symptoms, blood-stained discharge, displacement of the eye, severe pain [35].

#### *Magnetic resonance imaging*

- The prevalence of incidental changes on MRI is considerable and therefore MRI is of only limited use in the diagnosis of rhinosinusitis [36].
- May be needed to exclude anterior cranial floor tumours as a cause of unexplained anosmia.

*Tests for asthma.* Measurements of lung function should be considered in all patients with CRS [e.g. peak expira-

tory flow rate (PEFR) and spirometry as detailed in the British Thoracic Society guidelines on the management of asthma] [37].

#### *Nasal biopsy and histology*

- May be useful in suspected cases of vasculitis, Wegener's granulomatosis, Churg-Strauss and sarcoidosis.
- Histology may change the diagnosis in 1% of surgically removed nasal polyps [38].

#### *Aetiology*

Underlying causes [39] should be investigated, see text box 3.

#### **Text box 3: Rhinosinusitis – aetiology and relevant tests**

- Allergy (skin prick tests/specific IgE)
- Immune deficiency, chronic infection (immunoglobulins/IgG subclasses/histology, culture of sinus swabs), sinus cultures are rarely helpful (bacterial biofilm) [40]
- Vasculitis/granulomatous/autoimmune (FBC, ESR, ANA, ACE, ANCA, biopsy)
- Aspirin sensitivity (history, inhaled or nasal lysine-aspirin challenge, oral aspirin challenge)
- Allergic fungal sinusitis (skin prick tests, total IgE, characteristic mucin, aspergillus-specific IgG and IgE, CT changes, silver stains on histological specimen)
- Systemic diseases including Wegener's granulomatosis, Churg Strauss disease, sarcoidosis may present with rhinosinusitis [41]. Therefore, evidence of adhesions, contact bleeding, crusting should prompt the relevant investigations including: FBC, ESR, eosinophil count, ACE, ANA, ANCA and nasal biopsy if required

#### *Treatment*

There are few well-conducted clinical trials in chronic rhinosinusitis. Further studies are needed in well-characterized patients. Advice on such trials exists [42]. Based on the evidence available initial therapy is medical and should aim to reduce symptoms and signs, improve quality of life and prevent disease progression or recurrence. CRS usually responds incompletely to therapy and may need to be continued long-term [43–45]. The evidence for various treatment modalities is given in Table 1 (adapted from Fokkens *et al.* [45]). There are also other recently published guidelines for the medical management of CRS in adults [39, 45–47].

*Nasal douching.* Nasal douching is a safe, inexpensive treatment commonly used in mainland Europe. Evidence

Table 1. Therapy in chronic rhinosinusitis\* adapted from Fokkens et al. [45]

Therapy	Grade of recommendation	Clinically relevant
Nasal saline douche [11, 50, 53, 108–111]	A	Yes (for additional therapy)
Topical corticosteroid [112–116]	A	Yes
Addition of oral antihistamine in allergic patients [117, 118]	A	Yes for itching, sneezing and rhinorrhoea
Oral antibiotic therapy, long-term ~12 weeks [68, 119–123]	A	Yes
Oral antibiotics – short-term < 2 weeks [124–127]	C	Acute severe exacerbation only
Allergen avoidance in allergic patients	D	Yes
Mucolytics [128]	C	No
Bacterial lysates [129]	C	No
Antibiotics – topical [112, 130–133]	D	No
Proton pump inhibitors [134–136]	D	No
Steroid – oral	D	No
Decongestant oral/topical	D	No
Antimycotics – systemic	D	No
Immunotherapy	D	No
Phytotherapy	D	No
Antimycotics – topical [69, 71, 137, 138] <sup>†</sup>	D	No

\*Some of the cited studies also included patients with nasal polyposis in addition to CRS. Acute exacerbations of CRS should be treated like acute rhinosinusitis.

<sup>†</sup>Two negative studies (*level of evidence* = 1 –) and one positive study (*level of evidence* = 2+). CRS, chronic rhinosinusitis.

exists that saline douching reduces symptoms of CRS [48–53] (*grade of recommendation* = A). It is a safe and inexpensive treatment.

#### Adverse events

- Sodium load should be considered in hypertensive patients.

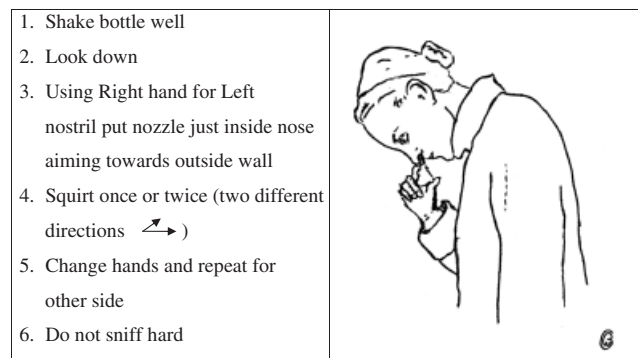
#### Place in therapy

- Addition to therapy in chronic rhinosinusitis, nasal polyposis and rhinitis.
- Effective in primary ciliary dyskinesia [54].

#### Topical intra-nasal corticosteroids

- Act by suppression of inflammation at multiple points in the inflammatory cascade [55].
- Nasal drops are preferable for nasal polyposis and probably also for chronic rhinosinusitis. These should be used in the 'head upside down' position in order to reach the ostiomeatal complex (OMC), see Fig. 1b.
- Bioavailability varies considerably. Systemic absorption is negligible with mometasone and fluticasone, modest for the remainder and high for betamethasone and dexamethasone, which should be used in the short-term only [56–58].
- Long-term growth studies in children using fluticasone, mometasone and budesonide have reassuring safety data, unlike beclomethasone [43, 59–62].
- Concomitant treatment with CYP3A inhibitors such as itraconazole or ritonavir may increase the systemic

#### (a)



#### (b)

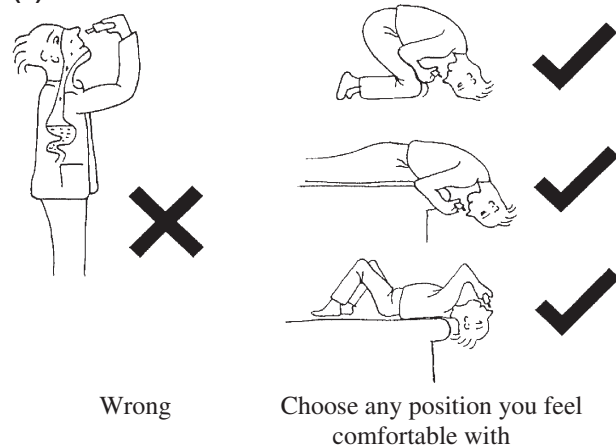


Fig. 1. Chronic rhinosinusitis (non-polypoid). (a) Correct procedure for the application of nasal sprays. (b) Correct procedure for the installation of nasal drops.

bioavailability of intra-nasal corticosteroids (INS) [63, 64].

#### Adverse events

- Local nasal irritation, sore throat and epistaxis affect around 10% of users.
- Benzalkonium chloride is used as a preservative in all topical corticosteroids except Rhinocort™ nasal spray and Flixonase™ nasules, and may irritate the nose, but does not adversely affect mucociliary clearance [65].
- Reduction of local adverse effects with nasal sprays can probably be achieved by correct use, see Fig. 1a (*grade of recommendation = D*).
- Hypothalamic-pituitary axis suppression may occur when multiple sites are treated with topical corticosteroids in the same person (e.g. skin, nose and chest). It is advisable to monitor growth in children [66].
- Raised intra-ocular pressure has been described with INS [67] and patients with a history of glaucoma should be monitored more closely.

#### Place in therapy

- First-line therapy for rhinosinusitis.
- Topical steroid drops should be used initially in nasal polyposis and in cases with severe obstruction.

**Antibiotics.** Short-term antibiotics (2 weeks) can be used for acute exacerbations of rhinosinusitis (*grade of recommendation = D*). Trials of long-term oral antibiotics ( $\geq 12$  weeks), especially macrolides, have demonstrated symptomatic and objective improvement similar to endoscopic sinus surgery [68] (*grade of recommendation = A*). The improvement shown increases with time and may relate to anti-inflammatory reactions in macrolides.

**Antifungals.** Placebo-controlled trials of amphotericin nasal douching are negative [69–72]. Oral terbinafine has also failed to show any activity under double-blind conditions [73].

**Intra-nasal decongestants.** The  $\alpha_1$ -agonist ephedrine (as nasal drops) and  $\alpha_2$ -agonist xylometazoline (available as nasal drops or spray for adults and children over 3 months of age) are sympathomimetics that increase nasal vasoconstriction. Combined with a topical corticosteroid such as Dexamethasone-Rhinaspray duo™, short term use is helpful in exacerbations of rhinosinusitis with nasal blockage [68].

#### Adverse events

- Regular use can lead to rhinitis medicamentosa with tachyphylaxis to the drug and marked chronic nasal obstruction [74].

- Nasal irritation
- May increase rhinorrhoea.

#### Place in therapy

- Brief use of <10 days is advised in order to avoid rebound effect
  - for eustachian tube dysfunction when flying
  - in children with acute otitis media to relieve middle ear pain/pressure
  - post-URTI to reduce nasal/sinus congestion
  - To increase nasal patency before the intranasal administration of nasal steroids.

**Systemic glucocorticosteroids.** Oral corticosteroids should be used briefly and always in combination with a topical nasal corticosteroid. A suggested regime for adults is 0.5 mg/kg given orally in the morning with food for 5–10 days and are used for:

- Severe nasal obstruction
- Short-term rescue medication for uncontrolled symptoms on conventional pharmacotherapy
- Medical polypectomy – see section on nasal polyps (and text box 4).

**Surgery.** A randomized prospective study of patients with polypoid or non-polypoid CRS demonstrated that there was no difference between patients who received medical treatment (topical corticosteroid, nasal douching and long-term erythromycin) compared with those who underwent endoscopic sinus surgery combined with topical nasal steroids [68]. No placebo was included, and whereas both treatments improved asthma control, medical treatment was superior in the patients with associated nasal polyposis (*level of evidence = 2 –*).

Surgical intervention should be reserved for treatment failures and is indicated for:

- Drug-resistant inferior turbinate hypertrophy [75]
- Anatomical variations of the septum with functional relevance
- Anatomical variations of the bony pyramid with functional relevance
- Acute severe sinusitis/periorbital cellulitis unresponsive to intravenous antibiotics
- Different forms of unilateral nasal polyposis (antrochoanal polyp, solitary polyp) or therapy-resistant bilateral nasal polyposis
- CRS resistant to medical therapy
- Fungal sinus disease (mycetoma, invasive forms, AFS) or other pathologies unrelated to allergy (CSF leak, inverted papilloma, benign and malignant tumours, Wegener's disease, etc.).

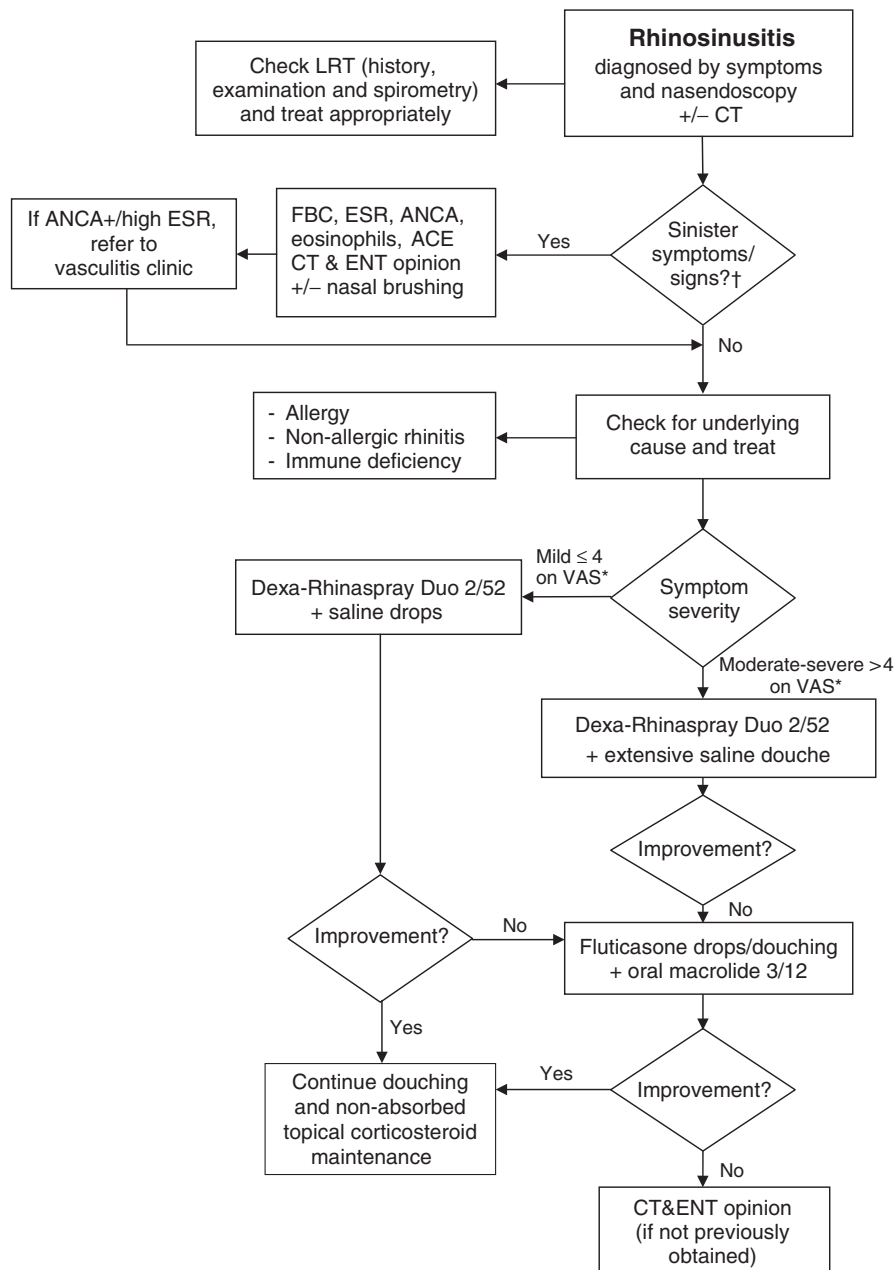


Fig. 2. Algorithm for the treatment of chronic rhinosinusitis (non-polypoid). †Sinister symptoms and signs include: bloody discharge, systemically ill, granulomatous mucosa, collapse of nose, septal perforation, unilateral disease, vasculitis, visual disturbance, severe headaches, frontal swelling, neurological signs, meningitis. \*VAS, visual analogue scale: a continuous horizontal line of 10 cm where: 0 cm indicates no complaints, 10 cm indicates severe complaints. The patient is asked to evaluate complaints over the past 14 days [107].

### Rhinosinusitis in children

Rhinosinusitis in children is a common problem, which may be related to underlying immune deficiency (innate or acquired) or to allergy, but frequently no pre-disposing factors are identified. Like otitis media with effusion (OME), rhinosinusitis usually resolves with maturation at around 7 years of age. Medical treatment including douching should be instigated, with surgery reserved for acute severe problems or for those patients

with severe chronic symptoms not responding to medical therapy [76]. There are guidelines for the treatment of paediatric rhinosinusitis [77].

An algorithm for the treatment of CRS (non-polypoid) is given in Fig. 2 (*grade of recommendation = D*).

### Nasal polyps (chronic polypoid rhinosinusitis)

Nasal polyps occur when the oedematous lining of the nasal cavity becomes dependant, blocking it to a variable



degree. Polyps usually start around the ostiomeatal complex, but can be found throughout the nose and sinuses. Nasal polyps are not associated with allergy but can be associated with asthma, aspirin sensitivity, cystic fibrosis, AFS and Churg–Strauss. Nasal polyps can be classified as eosinophil-rich, infective, or due to other causes. Eosinophilic polyps predominate in the United Kingdom and although SPTs are usually negative, the polyps may contain local polyclonal IgE of uncertain significance [78, 79].

#### *Signs and symptoms of nasal polyps*

- Nasal obstruction
- Rhinorrhoea
- Hyposmia/anosmia, decreased taste
- Post-nasal catarrh
- Secondary bacterial infection may occur when polyps block the sinus ostia.

#### *Diagnosis*

- Larger polyps can be seen at the nares and are distinguishable from inferior turbinate by their lack of sensitivity, yellowish grey colour and the ability to get between them and the side wall of the nose.
- Smaller polyps may only be visible on nasendoscopy.
- Unilateral polyps may be a sign of malignancy and should always be subject to ENT referral.
- At initial presentation all patients with polyps should be examined by an ENT surgeon.
- Children with nasal polyps should be referred for further testing for cystic fibrosis.

#### *Treatment*

*Medical polypectomy.* All patients should have a trial of medical treatment before surgery unless the nature of the polyps is in doubt. Smaller polyps may respond to topical corticosteroid only, initially betamethasone nasal drops [80–82].

Larger polyps may respond to a medical polypectomy (see text box 4).

#### **Text box 4: Medical polypectomy**

- Prednisolone 0.5 mg/kg each morning for 5–10 days PLUS
- Betamethasone nasal drops two drops per nostril tds in the 'head upside down' position (see Fig. 1b) for 5 days, then twice daily until the bottle runs out

Maintenance therapy with fluticasone (drops, spray) or mometasone (spray) is recommended as

these have lower bioavailability, unlike betamethasone nasal drops [83–86].

All forms of topical INS (sprays, drops) may delay the re-growth of nasal polyps [87, 88]. Polyps tend to recur, and it is recommended that treatment is continued for the long-term. However, there is no evidence for how long treatment should be continued although this will vary, with more aggressive inflammatory polyps rich in eosinophils and IL-5 requiring prolonged treatment. An algorithm for the treatment of polypoid CRS is shown in Fig. 3; see also Table 2.

#### *Anti-leukotrienes*

- There are no RCTs on the use of anti-leukotrienes in rhinosinusitis, but efficacy in nasal polyposis has been demonstrated [89].

#### *Adverse events*

- Usually well tolerated; occasional headache, gastrointestinal symptoms or rashes.
- Occasional reports of Churg–Strauss syndrome which may relate more to steroid withdrawal rather than a direct effect of the drug, although further long-term evaluation is needed.

#### *Place in therapy*

- Anti-leukotrienes may be used in patients with aspirin-sensitive rhinosinusitis, asthma [90] and nasal polyposis. Some patients with aspirin sensitivity appear to show marked improvement [91, 92], although at present, it is not possible to predict responders other than by use of a trial of therapy.

#### *Other treatment modalities*

- Antibiotics: open studies from Japan suggested that macrolides can reduce nasal polyps when used over several weeks or months [93], possibly via anti-inflammatory activity [68] (*level of evidence* = 2 – ; *grade of recommendation* = D).
- Azelastine: an open study suggests that this may have some benefit in nasal polyposis [94] (*level of evidence* = 2 – ; *grade of recommendation* = D).
- Aspirin desensitisation.
- Surgery will remove the obstructing tissue, but does not control the symptoms of rhinitis. Poor olfactory function may not be reversed by surgery. A randomized prospective study showed that medical treatment is superior to surgery when effects on the lower respiratory tract are considered [68].

#### **Allergic fungal rhinosinusitis**

This is rare in the United Kingdom, but more common in warmer climates such as the Southern USA and Australia.

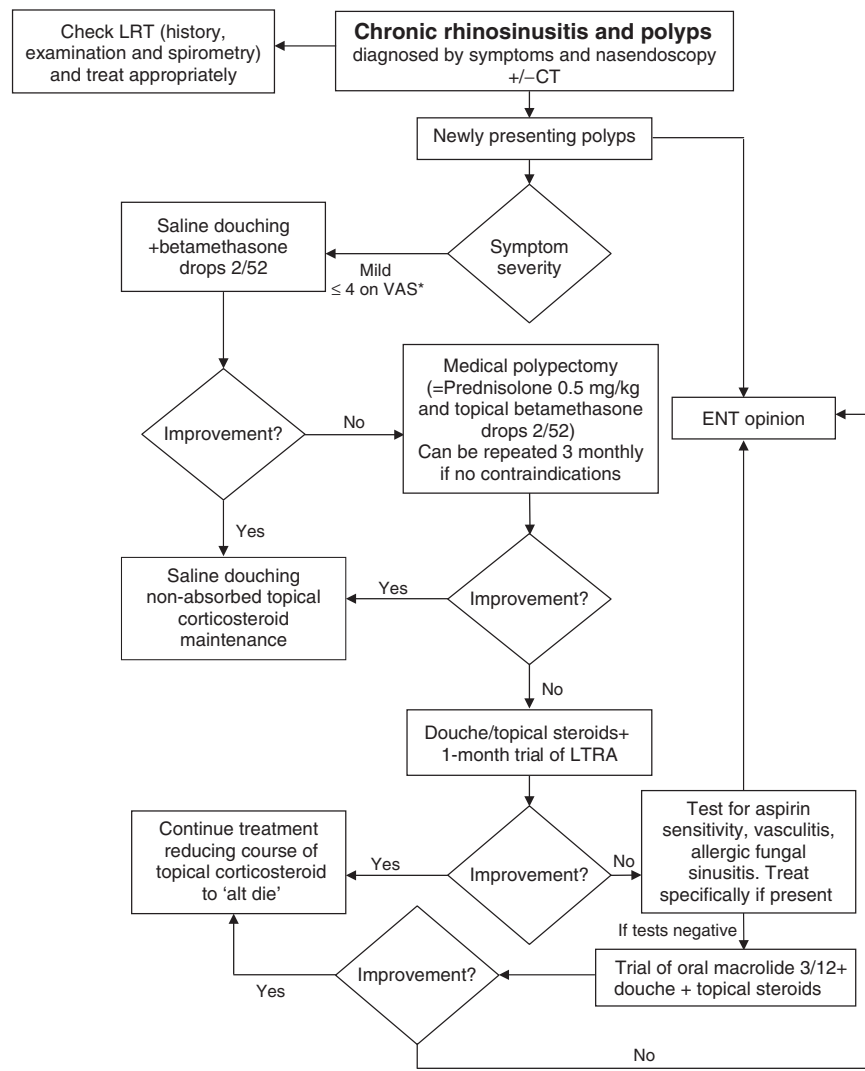


Fig. 3. Algorithm for the treatment of chronic rhinosinusitis and polyposis.

Table 2. Therapy in nasal polyposis adapted from Fokkens et al. [45]

Therapy	Grade of recommendation	Clinically relevant
Topical steroids [139–141]	A	Yes
Oral antihistamine in allergic patients [142]	A	Yes for itching, sneezing and rhinorrhoea
Nasal douche	A	Yes
Oral steroids [143–146]	A	Yes
Antileucotrienes [147–149]	C	Yes
Oral antibiotic long-term ~12 weeks [68, 123]	D	Yes for late relapse
Capsaicin [150, 151]	B	No
Proton pump inhibitors [152]	C	No
Oral antibiotic short-term < 2 weeks	D	No
Antimycotics – topical [100, 153]	D	No
Decongestant topical/oral	D	No
Mucolytics	D	No
Antimycotics – systemic	D	No
Immunotherapy	D	No
Phytotherapy	D	No
Topical antibiotics	D	No

*Criteria for the diagnosis of allergic fungal rhinosinusitis [95]*

- Polypoid chronic rhinosinusitis
- Specific anti-fungal IgE
- CT heterogeneity/expansion/erosion
- Eosinophilic mucin without fungal invasion
- Fungi in sinus contents

*Treatment of allergic fungal rhinosinusitis*

Allergic fungal rhinosinusitis requires surgery with the removal of all affected tissue, followed by topical corticosteroids. Oral anti-fungals are sometimes used, but evidence for their effectiveness is of poor quality [96] (*grade of recommendation = D*).

**Fungal rhinosinusitis**

Fungi and their spores are present in the air at all times, are naturally part of the respired air and can be detected in the normal nose. Usually, the host does not react to them. The majority of patients with nasal polyps have negative-SPTs to fungal allergens [78, 97, 98]. However, based on histological staining which demonstrated fungi in the eosinophilic nasal mucus of polyp patients, it was suggested that fungal hypersensitivity may be the cause of most chronic sinusitis and nasal polyposis [99]. Open studies of douching with antifungals such as amphotericin have been reported as beneficial [100]. However, all controlled studies have proved negative [69, 71, 72].

**Aspirin-sensitive nasal polyposis**

Some 5–8% of patients with nasal polyps have aspirin and NSAID sensitivity, rhinosinusitis and usually have concomitant (intrinsic) asthma [78]. This syndrome usually presents in the third and fourth decades and is more common in females and in non-atopics.

Ingestion of aspirin or an NSAID induces a reproducible reaction within 20–120 min. In any individual the form of the reaction is consistent and any combination of symptoms may occur including systemic upset with facial flushing, perspiration and intense lethargy, rhinorrhoea, nasal congestion, conjunctivitis and respiratory symptoms of cough and bronchospasm. Some individuals develop gastrointestinal symptoms. A severe reaction can include respiratory arrest and shock.

Aspirin sensitivity is associated with severe rhinosinusitis, and asthma, with increased intensity of eosinophilic inflammation and of cytokines, mainly IL-5. Surgery is less successful in aspirin-sensitive as compared with aspirin-tolerant individuals with relapse occurring earlier [101].

*Diagnosis of aspirin-sensitive nasal polyposis*

- Aspirin sensitivity should be suspected in severely affected polyp patients, especially those with recurrent polyps and intrinsic asthma.
- No blood test has sufficient sensitivity or specificity.
- The diagnosis rests upon either a clear history of two aspirin/NSAID-induced reactions or by aspirin challenge, which can be nasal, inhaled or oral.
- Nasal and bronchial challenge entails the use of lysine aspirin [102], which is a soluble form of aspirin.
- Nasal challenge, if negative, should be followed by graduated oral challenge.
- Aspirin challenge must be carried out only by doctors with appropriate experience and with full resuscitation facilities readily available.

*Management of aspirin-sensitive nasal polyposis*

- Patients should be warned to avoid all drugs with COX1 inhibitory activity.
- Selective COX2 inhibitors appear to be safe, but it has been suggested that the first dose should be administered in hospital under direct observation with monitoring for 2 h and resuscitation facilities available.
- Paracetamol (acetaminophen) is usually, but not always, tolerated in aspirin sensitive asthma. Single doses of up to 500 mg appear to be safe in 94% of patients [103].
- The role of diet avoiding preservatives, additives and high salicylate foods is controversial. In open studies a subset of patients have reported benefit.

*Aspirin desensitisation.* Aspirin-sensitive patients exhibit a refractory period after aspirin challenge [104]. During this time further doses do not lead to an acute deterioration in their condition. Regular administration of aspirin is associated with a lessening of both upper and lower respiratory tract symptoms, but does not lead to complete remission [105]. Oral aspirin desensitization followed by regular daily dosing may cause significant side-effects including gastrointestinal bleeding at high doses. However, there is some evidence suggesting that oral doses as low as 100 mg daily may be effective and this could potentially circumvent some of the adverse effects associated with oral aspirin [106]. However, this will require confirmation from further studies. The efficacy of the regular administration of topical intranasal lysine aspirin therapy remains under investigation.

**Churg–Strauss syndrome**

This is a combination of severe asthma, nasal polyposis, eosinophilia and eosinophilic vasculitis with granulomas. It should be suspected in patients with severe disease

requiring frequent courses of oral corticosteroids. About 50% of patients are ANCA positive. It is sensible to assess erythrocyte sedimental rate (ESR) and ANCA in severely affected patients with nasal polyps and asthma (see Fig. 2). If the diagnosis of Churg-Strauss syndrome is suspected, specialist referral to a vasculitis clinic is advisable for further management.

### Acknowledgements

The preparation of this document has benefited from extensive discussions within the Standards of Care Committee of the BSACI and we would like to acknowledge all the members of this committee for their valuable contribution namely, Andrew Clark, Tina Dixon, Pierre Dugué, Pamela Ewan, Sophie Farooque, Stephen Jolles, Nasreen Khan, Susan Leech, Ian Pollock, Richard Powell, Nasir Siddique and Sam Walker. Finally we would like to acknowledge the very valuable considerations and criticism we received from many BSACI members during the consultation process.

These *guidelines* inform the management of rhinosinusitis and nasal polyposis. Adherence to these guidelines does not constitute an automatic defence for negligence and conversely non-adherence is not indicative of negligence. It is anticipated that these guidelines will be reviewed every 5 years.

### References

- Powell RJ, Du Toit GL, Siddique N *et al.* BSACI guidelines for the management of chronic urticaria and angio-oedema. *Clin Exp Allergy* 2007; 37:631–50.
- Anand VK. Epidemiology and economic impact of rhinosinusitis. *Ann Otol Rhinol Laryngol Suppl* 2004; 193:3–5.
- Shashy RG, Moore EJ, Weaver A. Prevalence of the chronic sinusitis diagnosis in Olmsted County, Minnesota. *Arch Otolaryngol Head Neck Surg* 2004; 130:320–3.
- Chen Y, Dales R, Lin M. The epidemiology of chronic rhinosinusitis in Canadians. *Laryngoscope* 2003; 113:1199–205.
- Hickner JM, Bartlett JG, Besser RE, Gonzales R, Hoffman JR, Sande MA. Principles of appropriate antibiotic use for acute rhinosinusitis in adults: background. *Ann Intern Med* 2001; 134:498–505.
- Gwaltney JM Jr. Acute community acquired bacterial sinusitis: to treat or not to treat. *Can Respir J* 1999; 6 (Suppl. A): 46A–50A.
- Turner BW, Cail WS, Hendley JO *et al.* Physiologic abnormalities in the paranasal sinuses during experimental rhinovirus colds. *J Allergy Clin Immunol* 1992; 90:474–8.
- Nayak AS, Settupane GA, Pedinoff A *et al.* Effective dose range of mometasone furoate nasal spray in the treatment of acute rhinosinusitis. *Ann Allergy Asthma Immunol* 2002; 89:271–8.
- Meltzer EO, Charous BL, Busse WW, Zinreich SJ, Lorber RR, Danzig MR. Added relief in the treatment of acute recurrent sinusitis with adjunctive mometasone furoate nasal spray. The Nasonex Sinusitis Group. *J Allergy Clin Immunol* 2000; 106:630–7.
- Braun JJ, Alabert JP, Michel FB *et al.* Adjunct effect of loratadine in the treatment of acute sinusitis in patients with allergic rhinitis. *Allergy* 1997; 52:650–5.
- Rabago D, Zgierska A, Mundt M, Barrett B, Bobula J, Maberry R. Efficacy of daily hypertonic saline nasal irrigation among patients with sinusitis: a randomized controlled trial. *J Fam Pract* 2002; 51:1049–55.
- Lloyd GA, Lund VJ, Scadding GK. CT of the paranasal sinuses and functional endoscopic surgery: a critical analysis of 100 symptomatic patients. *J Laryngol Otol* 1991; 105: 181–5.
- Bachert C, Van Cauwenberge PB. Inflammatory mechanisms in chronic sinusitis. *Acta Otorhinolaryngol Belg* 1997; 51: 209–17.
- Marshall AH, Jones NS, Robertson IJ. CSF rhinorrhoea: the place of endoscopic sinus surgery. *Br J Neurosurg* 2001; 15:8–12.
- Flanagan P, Eccles R. Spontaneous changes of unilateral nasal airflow in man. A re-examination of the 'nasal cycle'. *Acta Otolaryngol* 1997; 117:590–5.
- West B, Jones NS. Endoscopy-negative, computed tomography-negative facial pain in a nasal clinic. *Laryngoscope* 2001; 111:581–6.
- Jones NS, Cooney TR. Facial pain and sinonasal surgery. *Rhinology* 2003; 41:193–200.
- Settipane GA, Chafee FH. Nasal polyps in asthma and rhinitis. A review of 6,037 patients. *J Allergy Clin Immunol* 1977; 59:17–21.
- Bush A. Primary ciliary dyskinesia. *Acta Otorhinolaryngol Belg* 2000; 54:317–24.
- Hurst JR, Donaldson GC, Wilkinson TM, Perera WR, Wedzicha JA. Epidemiological relationships between the common cold and exacerbation frequency in COPD. *Eur Respir J* 2005; 26:846–52.
- Roberts NJ, Lloyd-Owen SJ, Rapado F *et al.* Relationship between chronic nasal and respiratory symptoms in patients with COPD. *Respir Med* 2003; 97:909–14.
- Yung MW, Gould J, Upton GJ. Nasal polyposis in children with cystic fibrosis: a long-term follow-up study. *Ann Otol Rhinol Laryngol* 2002; 111:1081–6.
- Fergie N, Jones NS, Havlat MF. The nasal manifestations of sarcoidosis: a review and report of eight cases. *J Laryngol Otol* 1999; 113:893–8.
- Fukase S, Ohta N, Inamura K, Kimura Y, Aoyagi M, Koike Y. Diagnostic specificity of anti-neutrophil cytoplasmic antibodies (ANCA) in otorhinolaryngological diseases. *Acta Otolaryngol* 1994; 511 (Suppl.):204–7.
- Doty RL, Shaman P, Kimmelman CP, Dann MS. University of Pennsylvania smell identification test: a rapid quantitative olfactory function test for the clinic. *Laryngoscope* 1984; 94:176–8.
- Romero JN, Scadding G. Eosinophilia in nasal secretions compared to skin prick test and nasal challenge test in the diagnosis of nasal allergy. *Rhinology* 1992; 30:169–75.
- Stanley P, MacWilliam L, Greenstone M, Mackay I, Cole P. Efficacy of a saccharin test for screening to detect abnormal mucociliary clearance. *Br J Dis Chest* 1984; 78:62–5.

- 28 Sotomayor H, Badier M, Vervloet D, Orehek J. Seasonal increase of carbachol airway responsiveness in patients allergic to grass pollen. Reversal by corticosteroids. *Am Rev Respir Dis* 1984; 130:56–8.
- 29 Scadding G. Nitric oxide in the airways. *Curr Opin Otol Head Neck Surg* 2007; 15:258–63.
- 30 Prieto L, Berto JM, Gutierrez V, Tornero C. Effect of inhaled budesonide on seasonal changes in sensitivity and maximal response to methacholine in pollen-sensitive asthmatic subjects. *Eur Respir J* 1994; 7:1845–51.
- 31 Jiannetto DF, Pratt MF. Correlation between preoperative computed tomography and operative findings in functional endoscopic sinus surgery. *Laryngoscope* 1995; 105:924–7.
- 32 Bhattacharyya N, Jones DT, Hill M, Shapiro NL. The diagnostic accuracy of computed tomography in pediatric chronic rhinosinusitis. *Arch Otolaryngol Head Neck Surg* 2004; 130:1029–32.
- 33 Mason JD, Jones NS, Hughes RJ, Holland IM. A systematic approach to the interpretation of computed tomography scans prior to endoscopic sinus surgery. *J Laryngol Otol* 1998; 112:986–90.
- 34 Uzcategui N, Warman R, Smith A, Howard CW. Clinical practice guidelines for the management of orbital cellulitis. *J Pediatr Ophthalmol Strabismus* 1998; 35:73–9.
- 35 Jones NS. CT of the paranasal sinuses: a review of the correlation with clinical, surgical and histopathological findings. *Clin Otolaryngol Allied Sci* 2002; 27:11–7.
- 36 Cooke LD, Hadley DM. MRI of the paranasal sinuses: incidental abnormalities and their relationship to symptoms. *J Laryngol Otol* 1991; 105:278–81.
- 37 British Thoracic Society. British guideline on the management of asthma. *Thorax* 2003; 58 (Suppl. 1): i1–i94.
- 38 Diamantopoulos II, Jones NS, Lowe J. All nasal polyps need histological examination: an audit-based appraisal of clinical practice. *J Laryngol Otol* 2000; 114:755–9.
- 39 Scadding GK. Medical management of chronic rhinosinusitis. *Immunol Allergy Clin North Am* 2004; 24:103–18.
- 40 Harvey RJ, Lund VJ. Biofilms and chronic rhinosinusitis: systematic review of evidence, current concepts and directions for research. *Rhinology* 2007; 45:3–13.
- 41 Alobid I, Guilemany JM, Mullol J. Nasal manifestations of systemic illnesses. *Curr Allergy Asthma Rep* 2004; 4: 208–16.
- 42 Meltzer EO, Hamilos DL, Hadley JA. *et al.* Rhinosinusitis: developing guidance for clinical trials. *J Allergy Clin Immunol* 2006; 118:S17–61.
- 43 Salib RJ, Howarth PH. Safety and tolerability profiles of intranasal antihistamines and intranasal corticosteroids in the treatment of allergic rhinitis. *Drug Saf* 2003; 26:863–93.
- 44 Holm AF, Godthelp T, Fokkens WJ *et al.* Long-term effects of corticosteroid nasal spray on nasal inflammatory cells in patients with perennial allergic rhinitis. *Clin Exp Allergy* 1999; 29:1356–66.
- 45 Fokkens W, Lund V, Mullol J. *et al.* EPOS 2007: European position paper on rhinosinusitis and nasal polyps. *Rhinology* 2007; 45:1–139.
- 46 Fokkens W, Lund V, Bachert C *et al.* EAACI position paper on rhinosinusitis and nasal polyps. *Rhinology* 2005; (Suppl. 18): 1–87.
- 47 Fokkens W, Lund V, Bachert C *et al.* EAACI position paper on rhinosinusitis and nasal polyps executive summary. *Allergy* 2005; 60:583–601.
- 48 Brown CL, Graham SM. Nasal irrigations: good or bad? *Curr Opin Otolaryngol Head Neck Surg* 2004; 12:9–13.
- 49 Tomooka LT, Murphy C, Davidson TM. Clinical study and literature review of nasal irrigation. *Laryngoscope* 2000; 110:1189–93.
- 50 Taccariello M, Parikh A, Darby Y, Scadding G. Nasal douching as a valuable adjunct in the management of chronic rhinosinusitis. *Rhinology* 1999; 37:29–32.
- 51 Rabago D, Pasic T, Zgierska A, Mundt M, Barrett B, Maberry R. The efficacy of hypertonic saline nasal irrigation for chronic sinonasal symptoms. *Otolaryngol Head Neck Surg* 2005; 133:3–8.
- 52 Heatley DG, McConnell KE, Kille TL, Levenson GE. Nasal irrigation for the alleviation of sinonasal symptoms. *Otolaryngol Head Neck Surg* 2001; 125:44–8.
- 53 Shoseyov D, Bibi H, Shai P, Shoseyov N, Shazberg G, Hurvitz H. Treatment with hypertonic saline versus normal saline nasal wash of pediatric chronic sinusitis. *J Allergy Clin Immunol* 1998; 101:602–5.
- 54 Papsin B, McTavish A. Saline nasal irrigation: its role as an adjunct treatment. *Can Fam Physician* 2003; 49:168–73.
- 55 Fokkens WJ, Godthelp T, Holm AF, Klein-Jan A. Local corticosteroid treatment: the effect on cells and cytokines in nasal allergic inflammation. *Am J Rhinol* 1998; 12:21–6.
- 56 Homer JJ, Gazis TG. Cushing's syndrome induced by beta-methasone nose drops. In rhinological disease betamethasone should be regarded as systemic corticosteroid. *BMJ* 1999; 318:1355.
- 57 Perry RJ, Findlay CA, Donaldson MD. Cushing's syndrome, growth impairment, and occult adrenal suppression associated with intranasal steroids. *Arch Dis Child* 2002; 87:45–8.
- 58 Fowler PD, Gazis AG, Page SR, Jones NS. A randomized double-blind study to compare the effects of nasal fluticasone and betamethasone on the hypothalamo-pituitary-adrenal axis and bone turnover in patients with nasal polyposis. *Clin Otolaryngol Allied Sci* 2002; 27:489–93.
- 59 Allen DB. Systemic effects of intranasal steroids: an endocrinologist's perspective. *J Allergy Clin Immunol* 2000; 106:S179–90.
- 60 Moller C, Ahlstrom H, Henricson KA, Malmqvist LA, Akerlund A, Hildebrand H. Safety of nasal budesonide in the long-term treatment of children with perennial rhinitis. *Clin Exp Allergy* 2003; 33:816–22.
- 61 Schenkel EJ, Skoner DP, Bronsky EA *et al.* Absence of growth retardation in children with perennial allergic rhinitis after one year of treatment with mometasone furoate aqueous nasal spray. *Pediatrics* 2000; 105:E22.
- 62 Skoner DP, Rachelefsky GS, Meltzer EO *et al.* Detection of growth suppression in children during treatment with intranasal beclomethasone dipropionate. *Pediatrics* 2000; 105:E23.
- 63 Johnson SR, Marion AA, Vrhoticky T, Emmanuel PJ, Lujan-Zilbermann J. Cushing syndrome with secondary adrenal insufficiency from concomitant therapy with ritonavir and fluticasone. *J Pediatr* 2006; 148:386–8.
- 64 Skov M, Main KM, Sillesen IB, Muller J, Koch C, Lanng S. Iatrogenic adrenal insufficiency as a side-effect of combined

- treatment of itraconazole and budesonide. *Eur Respir J* 2002; 20:127–33.
- 65 McMahon C, Darby Y, Ryan R, Scadding G. Immediate and short-term effects of benzalkonium chloride on the human nasal mucosa in vivo. *Clin Otolaryngol Allied Sci* 1997; 22:318–22.
- 66 Allen DB, Meltzer EO, Lemanske RF Jr. *et al.* No growth suppression in children treated with the maximum recommended dose of fluticasone propionate aqueous nasal spray for one year. *Allergy Asthma Proc* 2002; 23:407–13.
- 67 Bui CM, Chen H, Shyr Y, Joos KM. Discontinuing nasal steroids might lower intraocular pressure in glaucoma. *J Allergy Clin Immunol* 2005; 116:1042–7.
- 68 Ragab SM, Lund VJ, Scadding G. Evaluation of the medical and surgical treatment of chronic rhinosinusitis: a prospective, randomised, controlled trial. *Laryngoscope* 2004; 114:923–30.
- 69 Ebbens FA, Scadding GK, Badia L *et al.* Amphotericin B nasal lavages: not a solution for patients with chronic rhinosinusitis. *J Allergy Clin Immunol* 2006; 118:1149–56.
- 70 Helbling A, Baumann A, Hanni C, Caversaccio M. Amphotericin B nasal spray has no effect on nasal polyps. *J Laryngol Otol* 2006; 120:1023–5.
- 71 Weschta M, Rimek D, Formanek M, Polzehl D, Podbielski A, Riechelmann H. Topical antifungal treatment of chronic rhinosinusitis with nasal polyps: a randomized, double-blind clinical trial. *J Allergy Clin Immunol* 2004; 113:1122–8.
- 72 Weschta M, Rimek D, Formanek M, Podbielski A, Riechelmann H. Effect of nasal antifungal therapy on nasal cell activation markers in chronic rhinosinusitis. *Arch Otolaryngol Head Neck Surg* 2006; 132:743–7.
- 73 Kennedy DW, Kuhn FA, Hamilos DL *et al.* Treatment of chronic rhinosinusitis with high-dose oral terbinafine: a double blind, placebo-controlled study. *Laryngoscope* 2005; 115:1793–9.
- 74 Scadding GK. Rhinitis medicamentosa. *Clin Exp Allergy* 1995; 25:391–4.
- 75 Passali D, Passali FM, Damiani V, Passali GC, Bellussi L. Treatment of inferior turbinate hypertrophy: a randomized clinical trial. *Ann Otol Rhinol Laryngol* 2003; 112:683–8.
- 76 Scadding GK, Caulfield H. Paediatric rhinosinusitis. In: Michael J. Gleeson (General editor), Scott – Brown's Otorhinolaryngology: Head and Neck Surgery. A. Hodder Arnold, 2008; 7Ed. SECTION IX: PAEDIATRIC OTOLARYNGOLOGY (Editor Ray Clarke).
- 77 Clement PA, Bluestone CD, Gordts F *et al.* Management of rhinosinusitis in children. *Int J Pediatr Otorhinolaryngol* 1999; 49 (Suppl. 1):S95–100.
- 78 Drake-Lee AB, Lowe D, Swanston A, Grace A. Clinical profile and recurrence of nasal polyps. *J Laryngol Otol* 1984; 98:783–93.
- 79 Bachert C, Gevaert P, Holtappels G, Johansson SG, Van CP. Total and specific IgE in nasal polyps is related to local eosinophilic inflammation. *J Allergy Clin Immunol* 2001; 107:607–14.
- 80 Lildholdt T. Surgical versus medical treatment of nasal polyps. *Rhinology* 1989; 8 (Suppl.):31–3.
- 81 Lund VJ. Diagnosis and treatment of nasal polyps. *BMJ* 1995; 311:1411–4.
- 82 Powers MR, Qu Z, LaGesse PC, Liebler JM, Wall MA, Rosenbaum JT. Expression of basic fibroblast growth factor in nasal polyps. *Ann Otol Rhinol Laryngol* 1998; 107:891–7.
- 83 Small CB, Hernandez J, Reyes A *et al.* Efficacy and safety of mometasone furoate nasal spray in nasal polyposis. *J Allergy Clin Immunol* 2005; 116:1275–81.
- 84 Stjarne P, Mosges R, Jorissen M *et al.* A randomized controlled trial of mometasone furoate nasal spray for the treatment of nasal polyposis. *Arch Otolaryngol Head Neck Surg* 2006; 132:179–85.
- 85 Keith P, Nieminen J, Hollingworth K, Dolovich J. Efficacy and tolerability of fluticasone propionate nasal drops 400 microgram once daily compared with placebo for the treatment of bilateral polyposis in adults. *Clin Exp Allergy* 2000; 30:1460–8.
- 86 Aukema AA, Mulder PG, Fokkens WJ. Treatment of nasal polyposis and chronic rhinosinusitis with fluticasone propionate nasal drops reduces need for sinus surgery. *J Allergy Clin Immunol* 2005; 115:1017–23.
- 87 Drake-Lee AB. Medical treatment of nasal polyps. *Rhinology* 1994; 32:1–4.
- 88 Badia L, Lund V. Topical corticosteroids in nasal polyposis. *Drugs* 2001; 61:573–8.
- 89 Ragab S, Parikh A, Darby YC, Scadding GK. An open audit of montelukast, a leukotriene receptor antagonist, in nasal polyposis associated with asthma. *Clin Exp Allergy* 2001; 31:1385–91.
- 90 Global Initiative for Asthma (GINA). Global strategy for asthma management and prevention, 1–92, 2006.
- 91 Dahlen B, Nizankowska E, Szczeklik A *et al.* Benefits from adding the 5-lipoxygenase inhibitor zileuton to conventional therapy in aspirin-intolerant asthmatics. *Am J Respir Crit Care Med* 1998; 157:1187–94.
- 92 Micheletto C, Tognella S, Visconti M, Pomari C, Trevisan F, Dal Negro RW. Montelukast 10 mg improves nasal function and nasal response to aspirin in ASA-sensitive asthmatics: a controlled study vs placebo. *Allergy* 2004; 59:289–94.
- 93 Yamada T, Fujieda S, Mori S, Yamamoto H, Saito H. Macrolide treatment decreased the size of nasal polyps and IL-8 levels in nasal lavage. *Am J Rhinol* 2000; 14:143–8.
- 94 Mosges R, Klimek L. Azelastine reduces mediators of inflammation in patients with nasal polyps. *Allergy Asthma Proc* 1998; 19:379–83.
- 95 Bent JP III, Kuhn FA. Allergic fungal sinusitis/polyposis. *Allergy Asthma Proc* 1996; 17:259–68.
- 96 Rains BM III, Mineck CW. Treatment of allergic fungal sinusitis with high-dose itraconazole. *Am J Rhinol* 2003; 17:1–8.
- 97 Stammberger H. Surgical treatment of nasal polyps: past, present, and future. *Allergy* 1999; 54 (Suppl. 53):7–11.
- 98 Grigoreas C, Vourdas D, Petalas K, Simeonidis G, Demeroutis I, Tsioulos T. Nasal polyps in patients with rhinitis and asthma. *Allergy Asthma Proc* 2002; 23:169–74.
- 99 Taylor MJ, Ponikau JU, Sherris DA *et al.* Detection of fungal organisms in eosinophilic mucin using a fluorescein-labeled chitin-specific binding protein. *Otolaryngol Head Neck Surg* 2002; 127:377–83.
- 100 Ricchetti A, Landis BN, Maffioli A, Giger R, Zeng C, Lacroix JS. Effect of anti-fungal nasal lavage with amphotericin B on nasal polyposis. *J Laryngol Otol* 2002; 116:261–3.

- 101 Gosepath J, Hoffmann F, Schafer D, Amedee RG, Mann WJ. Aspirin intolerance in patients with chronic sinusitis. *ORL J Otorhinolaryngol Relat Spec* 1999; **61**:146–50.
- 102 Nizankowska-Mogilnicka E, Bochenek G, Mastalerz L *et al*. EAACI/GA2LEN guideline: aspirin provocation tests for diagnosis of aspirin hypersensitivity. *Allergy* 2007; **62**:1111–8.
- 103 Szczeklik A, Gryglewski RJ, Czerniawska-Mysik G. Clinical patterns of hypersensitivity to nonsteroidal anti-inflammatory drugs and their pathogenesis. *J Allergy Clin Immunol* 1977; **60**:276–84.
- 104 Picado C. Aspirin intolerance and nasal polyposis. *Curr Allergy Asthma Rep* 2002; **2**:488–93.
- 105 Feldweg AM, Horan RF. Aspirin treatment of patients with aspirin intolerance, asthma, and nasal polyps. *Allergy Asthma Proc* 2001; **22**:377–82.
- 106 Gosepath J, Schafer D, Mann WJ. Aspirin sensitivity: long term follow-up after up to 3 years of adaptive desensitization using a maintenance dose of 100 mg of aspirin a day]. *Laryngorhinootologie* 2002; **81**:732–8.
- 107 Blom HM, van Rijswijk JB, Garrelds IM, Mulder PG, Timmermans T, Gerth van WR. Intranasal capsaicin is efficacious in non-allergic, non-infectious perennial rhinitis. A placebo-controlled study. *Clin Exp Allergy* 1997; **27**:796–801.
- 108 Bachmann G, Hommel G, Michel O. Effect of irrigation of the nose with isotonic salt solution on adult patients with chronic paranasal sinus disease. *Eur Arch Otorhinolaryngol* 2000; **257**:537–41.
- 109 Garavello W, Romagnoli M, Sordo L, Gaini RM, Di BC, Angrisano A. Hypersaline nasal irrigation in children with symptomatic seasonal allergic rhinitis: a randomized study. *Pediatr Allergy Immunol* 2003; **14**:140–3.
- 110 Garavello W, Di BF, Romagnoli M, Sambataro G, Gaini RM. Nasal rinsing with hypertonic solution: an adjunctive treatment for pediatric seasonal allergic rhinoconjunctivitis. *Int Arch Allergy Immunol* 2005; **137**:310–4.
- 111 Garavello W, Romagnoli M, Gaini RM. Hypertonic or isotonic saline for allergic rhinitis in children. *Pediatr Allergy Immunol* 2005; **16**:91–2.
- 112 Sykes DA, Wilson R, Chan KL, Mackay IS, Cole PJ. Relative importance of antibiotic and improved clearance in topical treatment of chronic mucopurulent rhinosinusitis. A controlled study. *Lancet* 1986; **2**:359–60.
- 113 Parikh A, Scadding GK, Darby Y, Baker RC. Topical corticosteroids in chronic rhinosinusitis: a randomized, double-blind, placebo-controlled trial using fluticasone propionate aqueous nasal spray. *Rhinology* 2001; **39**:75–9.
- 114 Lavigne F, Cameron L, Renzi PM *et al*. Intranasal administration of topical budesonide to allergic patients with chronic rhinosinusitis following surgery. *Laryngoscope* 2002; **112**:858–64.
- 115 Cuenat G, Stipon JP, Plante-Longchamp G, Baudoin C, Guerrier Y. Efficacy of endonasal neomycin-tixocortol pivalate irrigation in the treatment of chronic allergic and bacterial sinusitis. *ORL J Otorhinolaryngol Relat Spec* 1986; **48**:226–32.
- 116 Lund VJ, Black JH, Szabo LZ, Schrewelius C, Akerlund A. Efficacy and tolerability of budesonide aqueous nasal spray in chronic rhinosinusitis patients. *Rhinology* 2004; **42**:57–62.
- 117 Canonica GW, Tarantini F, Compalati E, Penagos M. Efficacy of desloratadine in the treatment of allergic rhinitis: a meta-analysis of randomized, double-blind, controlled trials. *Allergy* 2007; **62**:359–66.
- 118 Patou J, De SH, Van CP, Bachert C. Pathophysiology of nasal obstruction and meta-analysis of early and late effects of levocetirizine. *Clin Exp Allergy* 2006; **36**:972–81.
- 119 Nishi K, Mizuguchi M, Tachibana H *et al*. Effect of clarithromycin on symptoms and mucociliary transport in patients with sino-bronchial syndrome. *Nihon Kyobu Shikkan Gakkai Zasshi* 1995; **33**:1392–400.
- 120 Gandhi A, Brodsky L, Ballou M. Benefits of antibiotic prophylaxis in children with chronic sinusitis: assessment of outcome predictors. *Allergy Proc* 1993; **14**:37–43.
- 121 Ichimura K, Shimazaki Y, Ishibashi T, Higo R. Effect of new macrolide roxithromycin upon nasal polyps associated with chronic sinusitis. *Auris Nasus Larynx* 1996; **23**:48–56.
- 122 Hashiba M, Baba S. Efficacy of long-term administration of clarithromycin in the treatment of intractable chronic sinusitis. *Acta Otolaryngol Suppl* 1996; **525**:73–8.
- 123 Scadding GK, Lund VJ, Darby YC. The effect of long-term antibiotic therapy upon ciliary beat frequency in chronic rhinosinusitis. *J Laryngol Otol* 1995; **109**:24–6.
- 124 Legent F, Bordure P, Beauvillain C, Berche P. A double-blind comparison of ciprofloxacin and amoxicillin/clavulanic acid in the treatment of chronic sinusitis. *Chemotherapy* 1994; **40** (Suppl. 1):8–15.
- 125 McNally PA, White MV, Kaliner MA. Sinusitis in an allergist's office: analysis of 200 consecutive cases. *Allergy Asthma Proc* 1997; **18**:169–75.
- 126 Subramanian HN, Schechtman KB, Hamilos DL. A retrospective analysis of treatment outcomes and time to relapse after intensive medical treatment for chronic sinusitis. *Am J Rhinol* 2002; **16**:303–12.
- 127 Namyslowski G, Misiolek M, Czequier E *et al*. Comparison of the efficacy and tolerability of amoxicillin/clavulanic acid 875 mg b.i.d. with cefuroxime 500 mg b.i.d. in the treatment of chronic and acute exacerbation of chronic sinusitis in adults. *J Chemother* 2002; **14**:508–17.
- 128 Szmaja Z, Golusinski W, Mielcarek-Kuchta D, Laczowska-Przybylska J. Use of mucolytic preparations (Mucosolvan) in selected diseases of the upper respiratory tract. Part II. *Otolaryngol Pol* 1997; **51**:480–6.
- 129 Heintz B, Schlenter WW, Kirsten R, Nelson K. Clinical efficacy of Broncho-Vaxom in adult patients with chronic purulent sinusitis – a multi-centric, placebo-controlled, double-blind study. *Int J Clin Pharmacol Ther Toxicol* 1989; **27**:530–4.
- 130 Scheinberg PA, Otsuji A. Nebulized antibiotics for the treatment of acute exacerbations of chronic rhinosinusitis. *Ear Nose Throat J* 2002; **81**:648–52.
- 131 Mosges R, Spaeth J, Berger K, Dubois F. Topical treatment of rhinosinusitis with fusafungine nasal spray. A double-blind, placebo-controlled, parallel-group study in 20 patients. *Arzneimittelforschung* 2002; **52**:877–83.
- 132 Leonard DW, Bolger WE. Topical antibiotic therapy for recalcitrant sinusitis. *Laryngoscope* 1999; **109**:668–70.
- 133 Desrosiers MY, Salas-Prato M. Treatment of chronic rhinosinusitis refractory to other treatments with topical antibiotic

- therapy delivered by means of a large-particle nebulizer: results of a controlled trial. *Otolaryngol Head Neck Surg* 2001; 125:265–9.
- 134 Weaver EM. Association between gastroesophageal reflux and sinusitis, otitis media, and laryngeal malignancy: a systematic review of the evidence. *Am J Med* 2003; 115 (Suppl. 3A):81S–9S.
- 135 Phipps CD, Wood WE, Gibson WS, Cochran WJ. Gastroesophageal reflux contributing to chronic sinus disease in children: a prospective analysis. *Arch Otolaryngol Head Neck Surg* 2000; 126:831–6.
- 136 Ulualp SO, Toohill RJ, Hoffmann R, Shaker R. Possible relationship of gastroesophagopharyngeal acid reflux with pathogenesis of chronic sinusitis. *Am J Rhinol* 1999; 13: 197–202.
- 137 Ponikau JU, Sherris DA, Weaver A, Kita H. Treatment of chronic rhinosinusitis with intranasal amphotericin B: a randomized, placebo-controlled, double-blind pilot trial. *J Allergy Clin Immunol* 2005; 115:125–31.
- 138 Ponikau JU, Sherris DA, Kita H, Kern EB. Intranasal antifungal treatment in 51 patients with chronic rhinosinusitis. *J Allergy Clin Immunol* 2002; 110:862–6.
- 139 Mygind N, Pedersen CB, Prytz S, Sorensen H. Treatment of nasal polyps with intranasal beclomethasone dipropionate aerosol. *Clin Allergy* 1975; 5:159–64.
- 140 Penttila M, Poulsen P, Hollingworth K, Holmstrom M. Dose-related efficacy and tolerability of fluticasone propionate nasal drops 400 microg once daily and twice daily in the treatment of bilateral nasal polyposis: a placebo-controlled randomized study in adult patients. *Clin Exp Allergy* 2000; 30:94–102.
- 141 Hadfield PJ, Rowe-Jones JM, Mackay IS. A prospective treatment trial of nasal polyps in adults with cystic fibrosis. *Rhinology* 2000; 38:63–5.
- 142 Haye R, Aanesen JP, Burtin B, Donnelly F, Duby C. The effect of cetirizine on symptoms and signs of nasal polyposis. *J Laryngol Otol* 1998; 112:1042–6.
- 143 Lildholdt T, Rundcrantz H, Bende M, Larsen K. Glucocorticoid treatment for nasal polyps. The use of topical budesonide powder, intramuscular betamethasone, and surgical treatment. *Arch Otolaryngol Head Neck Surg* 1997; 123:595–600.
- 144 Lildholdt T, Fogstrup J, Gammelgaard N, Kortholm B, Ulsoe C. Surgical versus medical treatment of nasal polyps. *Acta Otolaryngol* 1988; 105:140–3.
- 145 VanCamp C, Clement PA. Results of oral steroid treatment in nasal polyposis. *Rhinology* 1994; 32:5–9.
- 146 Damm M, Jungehulsing M, Eckel HE, Schmidt M, Theissen P. Effects of systemic steroid treatment in chronic polypoid rhinosinusitis evaluated with magnetic resonance imaging. *Otolaryngol Head Neck Surg* 1999; 120:517–23.
- 147 Mostafa BE, Abdel HH, Mohammed HE, Yamani M. Role of leukotriene inhibitors in the postoperative management of nasal polyps. *ORL J Otorhinolaryngol Relat Spec* 2005; 67:148–53.
- 148 Kieff DA, Busaba NY. Efficacy of montelukast in the treatment of nasal polyposis. *Ann Otol Rhinol Laryngol* 2005; 114:941–5.
- 149 Pauli C, Fintelmann R, Klemens C *et al.* Polyposis nasi – improvement in quality of life by the influence of leukotrien receptor antagonists. *Laryngorhinootologie* 2007; 86:282–6.
- 150 Filiaci F, Zambetti G, Luce M, Ciofalo A. Local treatment of nasal polyposis with capsaicin: preliminary findings. *Allergol Immunopathol (Madr)* 1996; 24:13–8.
- 151 Baudoin T, Kalogjera L, Hat J. Capsaicin significantly reduces sinonasal polyps. *Acta Otolaryngol* 2000; 120:307–11.
- 152 Passali D, Bernstein JM, Passali FM, Damiani V, Passali GC, Bellussi L. Treatment of recurrent chronic hyperplastic sinusitis with nasal polyposis. *Arch Otolaryngol Head Neck Surg* 2003; 129:656–9.
- 153 Hartsel SC, Benz SK, Ayenew W, Bolard J. Na<sup>+</sup>, K<sup>+</sup> and Cl<sup>-</sup> selectivity of the permeability pathways induced through sterol-containing membrane vesicles by amphotericin B and other polyene antibiotics. *Eur Biophys J* 1994; 23:125–32.